Producing complete dentures in an age-appropriate design

A contribution to the 12th International CANDULOR KunstZahnWerk Competition 2021

Koji Kainuma, Dental Technician

About the Author

Koji Kainuma is a dental technician from Japan. He is the owner of SwissPlus in Japan Aich-Pref Handa-City, which specializes in the production of functionally and esthetically ideal dentures. In order to acquire the technical skills and knowledge needed to meet the individual functional and esthetically demands of his patients, he participated in evidence-based trainings abroad, mainly in Switzerland. The courses focused on functional-esthetic diagnostics and rehabilitation according to the original Gerber® Method, with MDT Max Bosshart being his major tutor. In 2012, Koji Kainuma became a Certified Instructor of Candulor (Switzerland). Between 2017 and 2019, he was a part-time lecturer at Tokai Dental Technician School in Nagoya.

In 2021, he took the first place in the category "Best Documentation" of the 12th International CANDULOR KunstZahnWerk Competition 2021.

The master of modern art, Pablo Picasso, once stated: "Our goals can only be reached through a vehicle of a plan, in which we must fervently believe, and upon which we must vigorously act. There is no other route to success." This is true for the creation of artwork as for any other project we would like to start, including the fabrication of full dentures.

For those producing full dentures, the major challenge lies in conciliating the functional and individual, age-related esthetic demands. By mastering their art and fulfilling this task, dental technicians may have a sustainable positive impact on their patients' quality of life.

The fabrication of full dentures with a natural, individual appearance instead of the typical, high-gloss standard solution: This task took center stage in the 12th International CANDULOR KunstZahnWerk Competition 2021 of the prosthetics specialist Candulor. The participants were asked to produce upper and lower full dentures for a 71-year-old male patient.

Information about the case

The patient had lost his maxillary incisors at the age of 16 following an accident. At the time he presented in the dental office, he had already been edentulous for nine years. No orthodontic or surgical treatment had been performed. The

Fig. 1 — Initial situation: edentulous patient with dentures that need to be replaced.

Fig. 2 — Model of the maxilla.

existing prosthetic work – a 20-year-old maxillary denture and a reworked telescopic mandibular denture – was insufficient (fig. 1). The occlusal plane was tilted to the left side. Severe plaque was present especially in the posterior areas of both dentures. The patient's facial muscles were relaxed and his mouth opening was not restricted. Phonation was slightly irregular. There were no temporomandibular joint disorders, ridge crest issues or other diseases present. The impression was taken with a slight overextension of the peripheral borders. The patient complained about the poor esthetic and poor stability of the existing dentures. The patient had previously undergone splint therapy to optimize the vertical dimension of occlusion and the bite position as well as the orientation of the occlusal plane.

The upper and lower full dentures were to be produced on the basis of a detailed model analysis and documentation. The case had to be solved applying the dynamic occlusion concept according to the condylar theory of Prof. Dr. A. Gerber.

Apart from the description of the initial situation, the participants were provided with models of the mandible and maxilla, physiognomic bite rims (figs. 2 to 4), additional clinical photographs and an evaluation sheet. The labial contour of the enclosed bite index corresponded to the labial lip contact in the anterior region of the maxilla and the buccal cheek contact in the posterior region. The patient had an Angle Class III relationship. The participants were asked to utilize the tooth forms PhysioStar NFC+: upper jaw 776 and lower jaw 998 (shade A3) as well as Condyloform II NFC+: lower and upper jaw 36 (shade A3). The models had to be mounted in the mean value articulator with the aid of the enclosed bite index. The condylar path inclination had to be set to 15° both on the left and right.

The patient expressed the need for artificial gingiva and an age-appropriate, individual design of the dentures with a natural, individual positioning of the anterior teeth and good phonation. Good retention of the dentures and good cleanability were equally important to him.

Fig. 3 — Model of the mandible.

Fig. 4 — Bite index.

Assessment of the extraoral clinical situation

In order to define patient-specific needs with regard to the planned dentures, an assessment of the facial characteristics and the posture was first carried out with the aid of facial photographs (fig. 5). They revealed the following differences between the patient's right and left half of the body: the nasolabial fold was deeper on the left than on the right side of the face, while the mandible was protruding and slightly offset to the right side. The Angle Class III occlusion was clearly visible in the profile. The anterior teeth and lower jaw appeared to be out of alignment. Moreover, the patient's shoulders were at different levels, virtually in line with the inclined occlusal plane.



Fig. 5 — Patient's face in different angles: profile, three-quarter view and front – red lines highlighting the differences in shoulder level and irregular occlusal plane orientation.

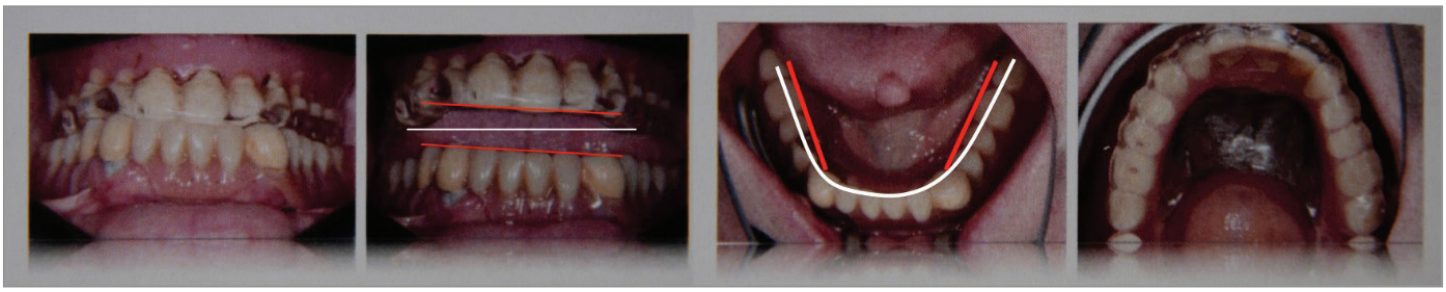

Fig. 6 — Intraoral images of the initial clinical situation – red lines highlighting the tilt of the maxillary and mandibular occlusal planes as well as a slightly narrowed dentition in the mandible.

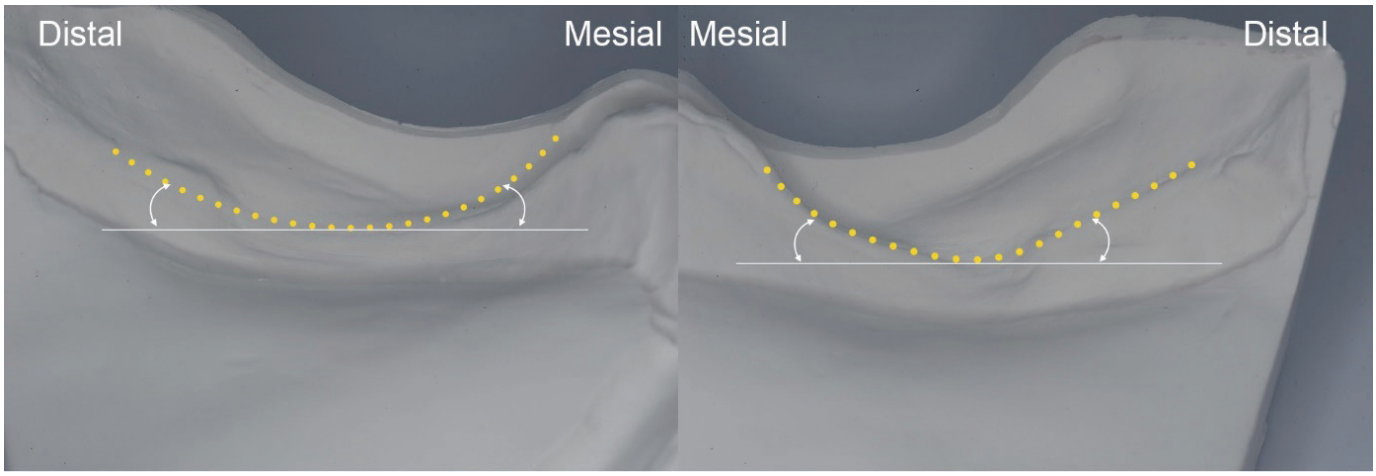

Fig. 7 — Model of the mandible: Steep upward slope of the alveolar ridge.

Assessment of the intraoral clinical situation

Based on the intraoral photographs and the physical models (figs. 6 and 7), the intraoral situation was assessed as well. The images confirmed the inclined occlusal plane (tilted to the left side) and a narrowed dentition in the mandible, while the premolars were in a normal position. Oral hygiene was compromised.

The maxillary model had large nodules and the incisive papillae were located on the labial side, which is characteristic of an Angle Class III relationship. On the mandibular model, a steep upward slope of the alveolar bone toward the first molar was clearly visible (fig. 7). Consequently, an adequate strategy needs to be developed to prevent movement of the denture that is usually caused by such a steep slope. Moreover, the alveolar ridge appeared to be very thin in the anterior region and formed a large labial undercut. In order to ensure proper lip support in this area, it would be necessary to block out this undercut. Moreover, comparing both models, a discrepancy between the alveolar ridge width in the positions of the maxillary and mandibular left first molars was detected. The mandible was wider in this position than the maxilla, which would necessitate a more labial positioning of the mandibular compared to the maxillary tooth. Consequently, a unilateral crossbite would be indicated in this area to establish a stable occlusion.

Definition of the treatment goals

Based on these findings and on the individual desires of the patient, the following treatment goals were defined: we were to produce full dentures with natural artificial gingiva and an age-appropriate, individual design with the desired

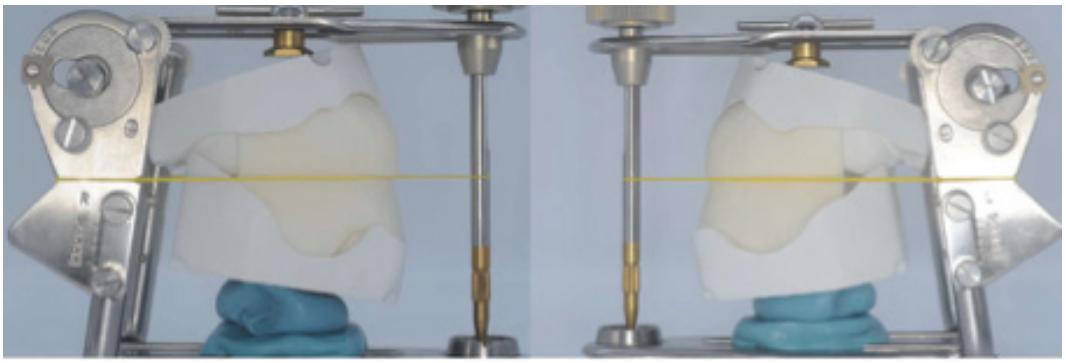

Fig. 8 — Bite index and models in the articulator, Camper's plane indicated as a reference.



Fig. 9 — Mounted models after removal of the bite index.

Fig. 10 — Drawing the outline of the alveolar ridge profile ...

natural positioning of the anterior teeth leading to a faultless phonation. The dentures should offer secure retention for high wear comfort and a great cleanability. Moreover, the need to create sufficient space for the tongue was noted, as it would not be automatically realizable.

Preparatory measures and articulation

Initially, the master casts were duplicated with the aid of silicone impression material and a copy of the bite index was produced. Afterwards, the original bite index was placed on the models, which were mounted in the articulator (fig. 8). As specified, the articulator was set to a condylar path inclination of 15° on both sides. Using the Camper's plane as a reference, it is possible to transfer the maxillomandibular relationship and the vertical dimension recorded in the dental office. Figure 9 shows the mounted models without the bite index in the articulator.

Model analysis

Before starting to set up the teeth, it is essential to determine the optimal positions and orientation of the denture teeth as well as the design of the denture base with the aid of a detailed model analysis developed for the concept of Prof. Gerber. Only in this way, it will be possible to prevent dysfunctional movements such as a tilting of the dentures on the atrophic ridges or an unwanted forward-downward movement of the lower denture during chewing (proglissement).

In the first step, the alveolar ridge profile was marked on the model base using a profile compass (fig. 10). Then, the masticatory center was defined by drawing a line that touches the lowest point of the alveolar ridge profile and runs parallel to the occlusal plane. The contact point of both lines represents the masticatory center, which should be occupied by the first molar as the largest chewing element. This line was extended over the alveolar ridge (fig. 11). The setup limits (stop lines) were added, as were other statically relevant positions

Fig. 11 — … and relevant statical landmarks onto the model base.

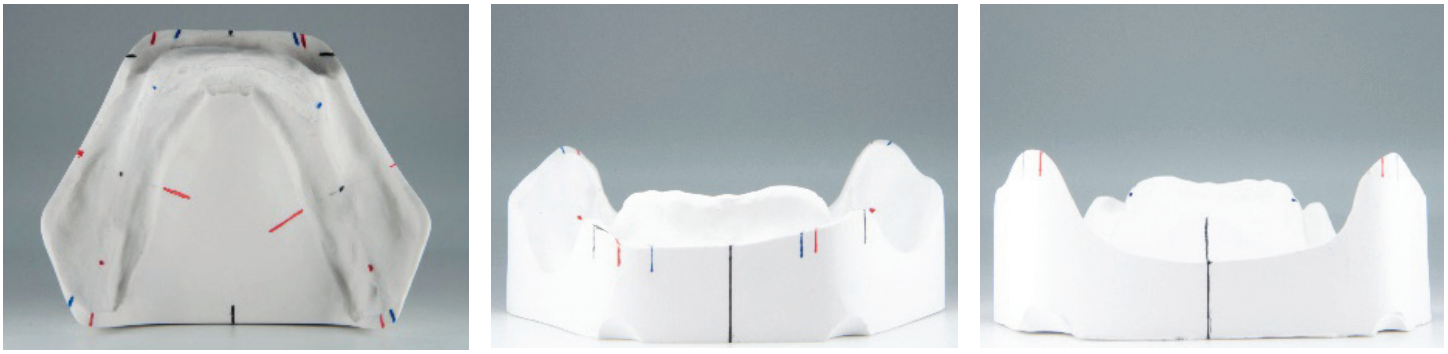

Fig. 12 — Statically relevant lines and points marked on the mandibular model.

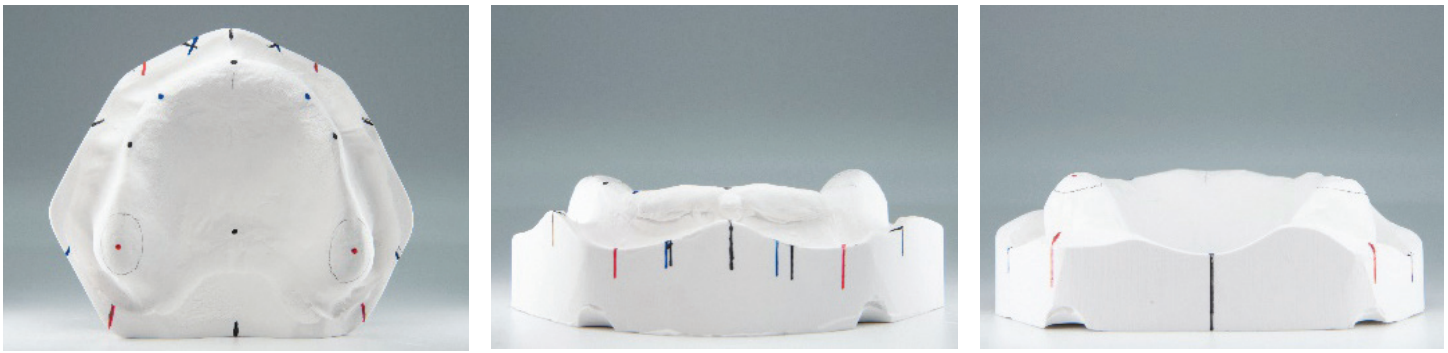

Fig. 13 — Statically relevant lines and points marked on the maxillary model.

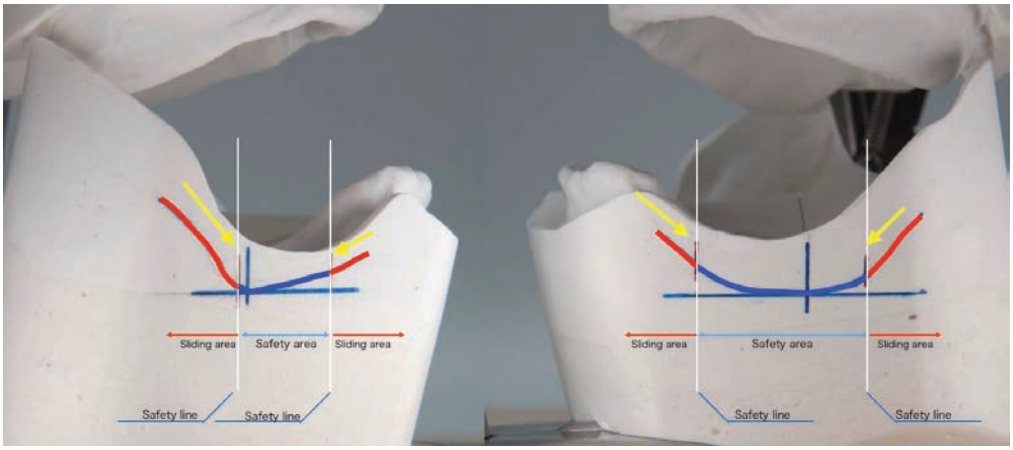

Fig. 14 — Masticatory center, stop line and safety area in which the posterior teeth may be set up.

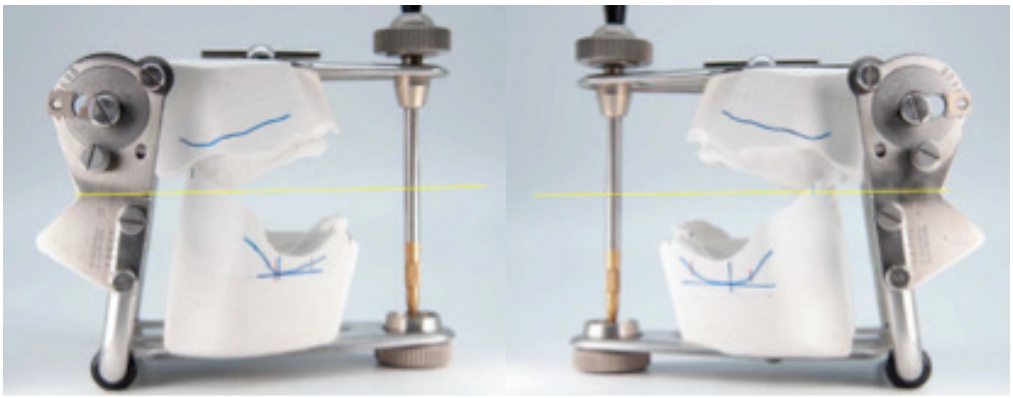

Fig. 15 — Checking of the determined occlusal plane (blue line on the outside of the maxillary model) in comparison with the Camper's plane (yellow line).

on the mandibular model's occlusal surface (a point indicating the canine / first premolar region, and two points indicating the midline, connected to draw a line on the outside of the model base). Figure 12 shows the lines drawn on the mandibular model. On the model of the maxilla, the midline of the model, middle of the alveolar ridge in the canine / first premolar and molar regions were marked, as were the ends of the static line (line connecting the points on the alveolar ridge) and the midline on the outside of the model (fig. 13).

Finally, the jaw movements and the occlusal plane has to be checked again (figs. 14 and 15). The more information is recorded on the model, the easier it becomes to assess the position of the alveolar ridge, the bite situation (normal bit on the right, crossbite on the left side) and the optimal position of each tooth to be set up. In this way, the tooth setup and denture design become highly predictable and the risk of errors is minimized.

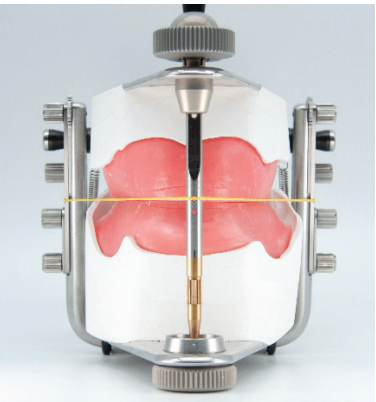

Fig. 16 — Copy of the silicone index placed on the models mounted in the articulator.



Fig. 17 — Mandibular wax denture base and silicone index …



Fig. 18 — … used to check the space available for the denture base.

Fig. 19 — Edge-to-edge bite indicated by the bite index in the anterior region.

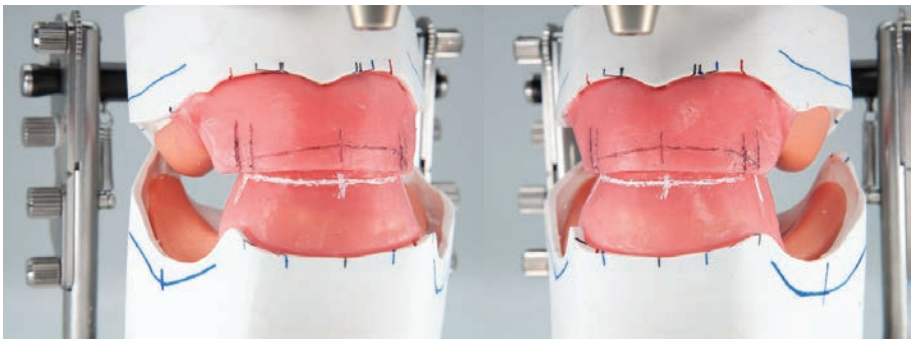

Fig. 20 — A posterior crossbite is indicated on the left side.

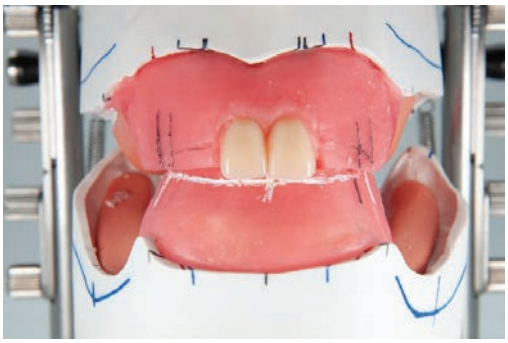

Fig. 21 — Setup of the maxillary central incisors.

Wax denture base

The copied bite index was mounted in the articulator for evaluation (fig. 16) and then transformed into the wax denture base for the mandibular and maxillary dentures. For this purpose, cervical contouring was performed in the anterior area. In this way, it is possible to optimize the lip support provided by the denture base. The anterior position was subsequently confirmed with the aid of a silicone index, which also allowed for a check of the clearance (figs. 17 and 18). Then, the posterior areas were reduced.

Anterior tooth setup

The tooth setup according to Prof. Gerber starts in the anterior region. The selected teeth, PhysioStar NFC+ in the shade A3, offer a natural surface texture, shade gradient and color appearance. By faithfully reproducing the bite index, the anterior teeth would provide proper lip support and produce an esthetically pleasing outcome. However, this meant that an anterior edge-to-edge bite needed to be established in the present case (fig. 19). The need for a posterior crossbite on the left side becomes evident in figure 20.

What followed was the setup of the maxillary anterior teeth, starting with the central incisors, proceeding with the lateral incisors and ending with the canines (figs. 21 and 22). In the mandible, the canines were placed first (fig. 23). Then, the central incisors and, in a last step, the lateral incisors were set up as well (figs. 24 and 25). The reason for the slight spacing in the mandibular anterior region is that only in this way, it is possible to create sufficient space for the tongue.

Posterior tooth setup

In the posterior region, Condyloform II NFC+ teeth were placed according to Prof. Gerber's dynamic occlusion concept. The selected tooth forms offer an anatomically beneficial occlusal morphology fitting the age of the patient. They support a lingualized occlusion and allow for a joint form-related guidance.

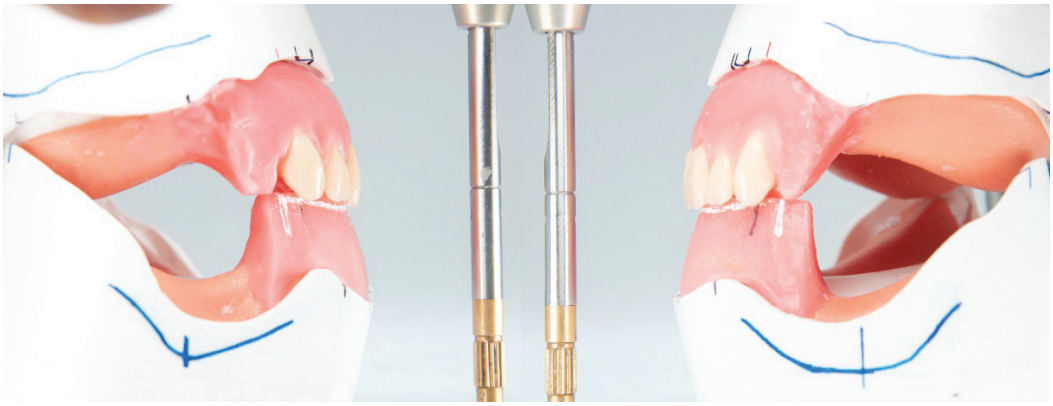

Fig. 22 — Setup of the maxillary anterior teeth completed.

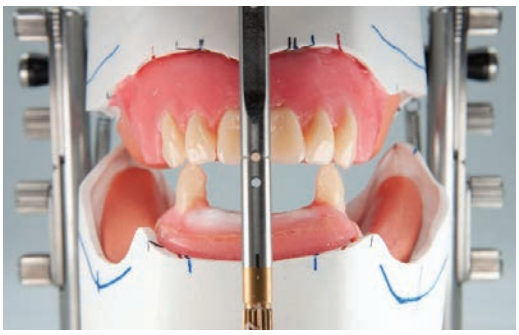

Fig. 23 — Positioning of the mandibular canines.

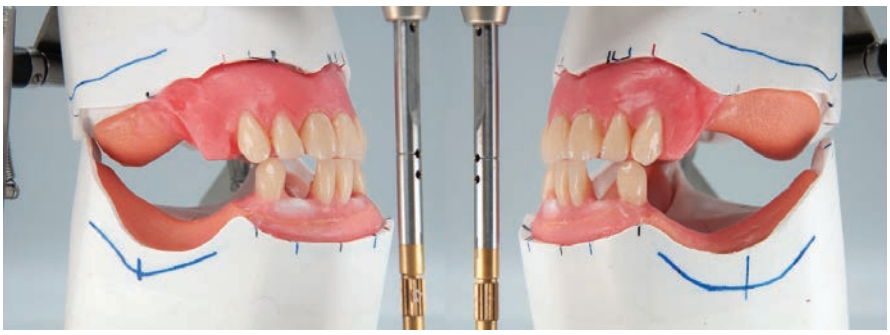

Fig. 24 — Setup of the mandibular central incisors.

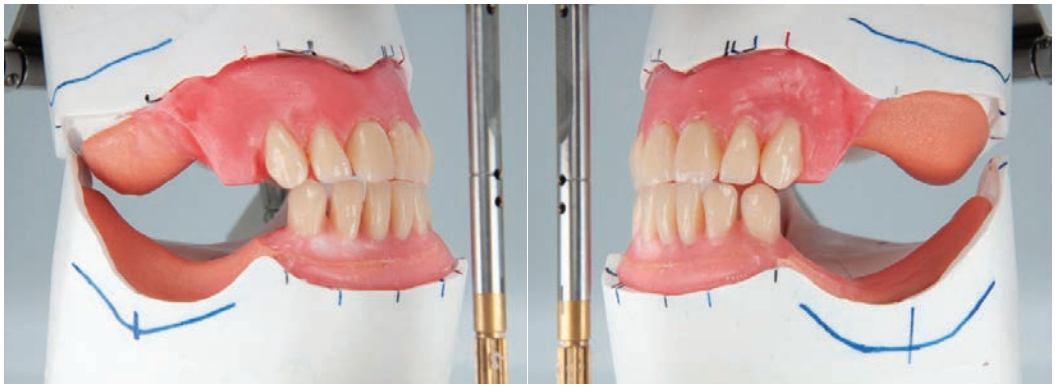

Fig. 25 — Setup of the mandibular anterior teeth completed.

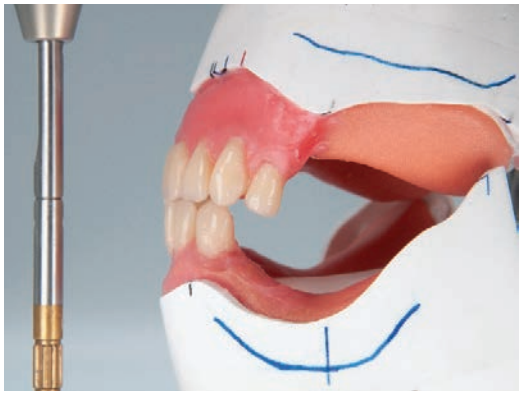

Fig. 26 — Start of the setup in the posterior region.

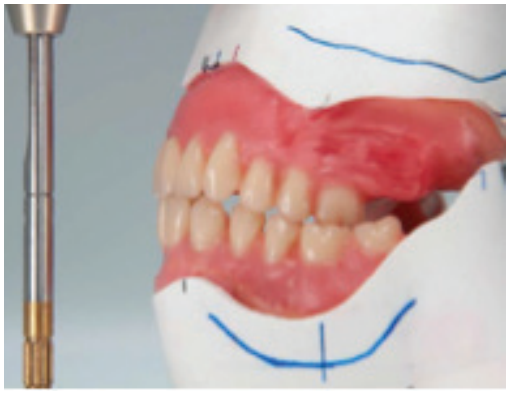

Fig. 27 — Positioning and cervical contouring of the mandibular second molar. The crossbite is established to provide a stable occlusion.

According to the planning, a Class III relationship with a unilateral crossbite on the left side and a normal bite on the right was established to provide stable occlusion and improve the chewing ability. The setup started with the maxillary left first premolar, which appears next to the canine when viewed from the frontal plane. Both teeth are esthetically very important. The premolar was positioned before tuning its cervical contour (fig. 26). The same was done for the mandibular first premolar, the lower and upper second premolars, the lower and upper first molars and finally, the lower second molar in the indicated order (fig. 27). The posterior teeth on the right side were set up in the same order and manner.

Design of the denture base

Figure 28 shows the wax denture after optimization of

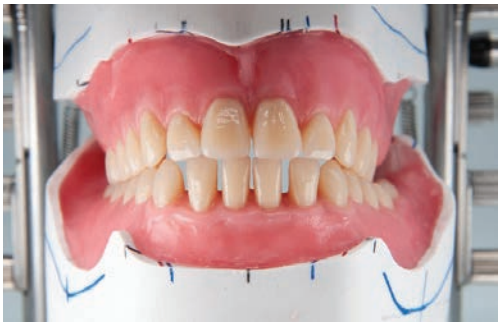

Fig. 28 — Wax denture base after optimization of the labial morphology.

Fig. 29 — Maxillary and mandibular wax dentures with the anterior teeth adjusted to open contacts slightly.

Fig. 30 — Checking of the occlusal contact points in centric occlusion with red Artikont articulation ribbon (Candulor).



Fig. 31 — Verification of the tooth positions on the alveolar ridge.

Fig. 32 — Silicone keys produced over the wax-up.

the labial morphology. The design was based on information obtained from the model analysis. It revealed that narrow arches allowing for a tooth-to-tooth contact would be esthetically more pleasing, but would not allow for proper tongue posture due to space limitations. Instead, it would force the tongue backward against the pharyngeal wall. A compressed airway and improper pronunciation would be the result. It is essential to check if the space created for the tongue is sufficient to prevent these issues.

At the end, the anterior teeth were slightly adjusted and the contacts opened a little more to optimize the tongue space (fig. 29). The setup phase was completed by a checking of the occlusal contacts (figs. 30) and a verification of the tooth positions on the alveolar ridges with the aid of a Static Pointer (fig. 31).

Denture production

For the fabrication of the final dentures, silicone keys were produced over the models with wax-up and teeth (fig. 32). The lower part of the polymerization device (Polymaster) was filled with plaster and the silicone keys with wax-up and models were invested. Plaster was also applied to the lid of the Polymaster and the model to fixate the model on the lid. Subsequently, the models were removed and the denture teeth were placed into the keys (fig. 33). An individual shading of the gingiva was obtained by combining different shades of the AESTHETIC BLUE Cold-Curing Denture Base Material. Special color effects can be obtained with AESTHETIC Intensive Colors, which are applied directly to the silicone key and teeth and may be dissolved in the AESTHETIC BLUE denture base monomer (fig. 34). This ensures that they will form a unified whole with the rest of the denture base. Figure 35 shows the dentures after polymerization completion.

For a final check of the static and dynamic occlusion, the dentures were placed on the models and mounted in the articulator again. Artikont articulation ribbon (80 µm) was used in different colors to enable the distinction between centric relation (red), lateral movements to the left and right (blue), and protrusion and retrusion (green) (figs. 36



Fig. 33 — Invested silicone keys with denture teeth (basal view).

Fig. 34 — Individualization of a denture base with a brush.

Fig. 35 — Polymerized dentures.

Fig. 36 — Occlusal contact points in centric relation.

to 38). The red marks highlight the most important contact points as the starting points of the tooth-to-tooth contact between upper and lower teeth. The blue marks confirmed that the path of the mandible during natural lateral movements was correct, while the green marks confirmed proper dynamics during protrusion and retrusion of the mandible.

Treatment outcome

Figures 39 to 41 show the completed dentures. The upper and lower anterior teeth are arranged in a natural position that takes advantage of the typical characteristics of an Angle Class III occlusion. The edge-to-edge bite and the slight spacing in

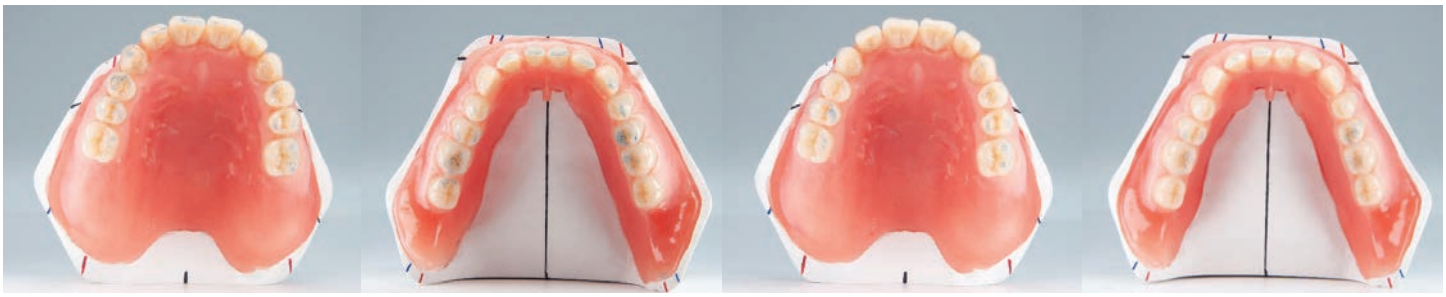

Fig. 37 — Occlusal contact points with lateral movements to the right (above) and to the left.

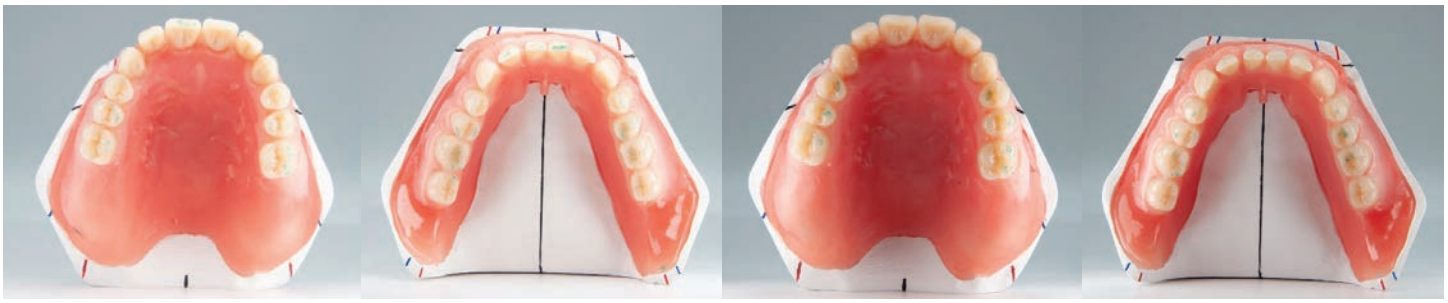

Fig. 38 — Occlusal contact points with protrusion (above) and retrusion.

Fig. 39 — Final treatment outcome – occlusal view.

Fig. 40 — Completed dentures in the articulator.

Fig. 41 — Frontal and lateral views of the completed work.

the anterior region are responsible for an individual look. The tongue space is increased, which positively affects the previously irregular phonation. The age-appropriate design of the gingiva has been realized by using Candulor AESTHETIC Intensive Colors, which allow for natural shade effects. Due to proper contouring and polishing, plaque retention on the dentures is minimized and oral hygiene can be managed more easily.

Conclusion

The present case highlights the importance of detailed planning and documentation within denture production procedures. It helps internalize the patient's individual functional and esthetic demands, allows us to identify possible challenges early and gives us the time needed to develop a suitable solution. In this way, it is usually easy to avoid unpleasant surprises in the production phase, so that great outcomes are obtained at the first go and minimal adjustments are necessary. In the end, we are rewarded for our planning effort by happy patients, whose quality of life is improved by age-appropriate, well-fitting dentures. ■